

Young Male's Post Appendectomy Complication of Pulmonary Thromboembolism

Hashem Shemshadi, MD.¹; Ahmad Ali Akbari Kamrani, PhD.
University of Social Welfare and Rehabilitation Sciences, Tehran, Iran

Mahyar Ghafoori, PhD.
Tehran University of Medical Sciences, Tehran, Iran

The main goal of this report was to share with clinicians an atypical presentation of pulmonary thromboembolism (PTE) in a young male's post-appendectomy, whom he had no significant predisposing factors for such disease. The case also introduced for re-examining the challenges of PTE clinical manifestations which may mimic other differential diagnosis.

PTE is an abrupt blockage of the pulmonary artery by a thrombus. Such thrombus is generated by a blood clot which has been formed, separated and migrated from the leg and/or pelvic veins toward the lung. The lung tissue's circulation is impaired which later episode results hypoxia and infarction. These events initiate a set of PTE clinical manifestations .

Keywords: post-appendectomy, surgical complication, deep vein thrombosis, pulmonary thromboembolism, immobilization

Submitted: 19 Jan. 2013

Accepted: 25 Feb 2013

Introduction

PTE is one of the most fatal complication post operatively and if occurs after a classical open appendectomy in a young male without having previous predisposing factors, is considered rare(1-8).Thrombus involved in PTE (9) is generated in the legs an/or the pelvic venous system. Rudolf Virchow, a German pathologist, in 1856 described such thrombus which is established based on three influencing factors of stasis, hypercoagulable state and the vessel endothelial damage (10-12).

In stasis due to immobilization, the blood being stagnated in circulation and causing its tendency for the clot formation (13, 14).This latter episode is more frequent in patients who remain in hospital bed for a long period of time. Hypercoagulable state such as blood hyperviscosity due to different reasons such consuming oral contraceptive pills or hereditary thrombophilia, considered as the second cumulative cause of thrombus formation. Damaged vessel's endothelial layer also provokes a suitable environment for such thrombus formation. Once the clot is formed, gets separated, mobilized and transferred to other remote sites via circulation, such as the patient's pulmonary artery. An abrupt blockage of circulation to the lung tissue, cause

appearance of an acute clinical manifestations of PTE such as sudden chest pain and respiratory difficulties, consequence apprehension, anxiety and a productive cough with bloody sputum.

Commonly, when a patient is inactive or remains prolongs in the hospital bed, due to major operations or having serious illnesses like cancer, are regarded as important risk factors for PTE. Taking contraceptive pills and genetically being susceptible for a hypercoagulable state may also have other reflecting factors for PTE. Usually, once the patients contract an unexpected and sudden blockage of their pulmonary artery (-ies), their clinical signs and symptoms of the disease begin quickly(15-17). The most frequent clinical presentation of patients with PTE, is the abrupt chest pain which aggravates with periods of respiration. Such chest pain is worse when the patient tries to cough or taking a deep inspiration. Gradually the cough is accompanied by a pink to bloody sputum. The patient may show anxiety, restlessness, tachycardia, cyanosis and death due to hypoxia.

Routinely, the definite diagnosis of PTE is difficult in the beginning. PTE's aforementioned clinical demonstrations may simulate the sign and the symptom other diseases such as heart attack, post-

1- All correspondences to Hashem Shemshadi,, Email: <shemshadii@gmail.com>

traumatic stress disorder and pneumonia (7, 18-20). But, the most probable diagnosis of PTE may be possible, if the evaluations of the patient's clinical along with obtaining some Para clinical tests, are performed readily. As soon as the preliminary diagnosis is established, the patient need to be admitted to the Hospital's ICU for the most appropriate and prompt initiation of appropriate therapy.

Presentation of the Case

A 20 year-old Afghan immigrant, presented with the typical sign and symptom of acute appendicitis at the Tehran's Payambaran Hospital. He did not have any significant health issues in the past. He underwent a classical open appendectomy under general anesthesia for an hour without any unusual event. Patient got ambulated from bed 6 hours post operatively and discharged from hospital with an acceptable clinical status after 48 hours post-surgery. During his perioperative period, he did not receive any anticoagulant therapy. A day after discharge, he returned to the above mentioned hospital emergency unit with the chief complaint of chest pain,

respiratory distress, fear, anxiety and a productive cough with blood. There were no signs of infection at the appendectomy site, except a mild local pain. Re-examining his past and present medical history was not remarkable for any problems such as pneumonia, asthma, family history of tuberculosis (TB), and/or any other significant diseases in the past. Vital sings revealed T=39, BP=100/70, RR= 32/m and HR= 100/m. Blood profile at the time of his hospital admission was WBC=12000(neutrophils 86%), Hb=15.4 GM%, INR=1.2, PT=13.9 (nl=12.5), the PT activity of 81.5%.Tests for thrombophilia such as protein C,S and anti-cardiolipin antibody were negative.

Due to the patient's anxiety, restlessness and unstable general appearance, we admitted him to the hospital's ICU and took him under serious observation. His vital signs, fluid intake and output and hypoxic conditions, managed appropriately. Thrombophilic hereditary disorder of blood coagulation tested and excluded by checking protein C,S and anti-cardiolipin antibody. Chest x-ray showed no significant pathological finding (Fig.1).

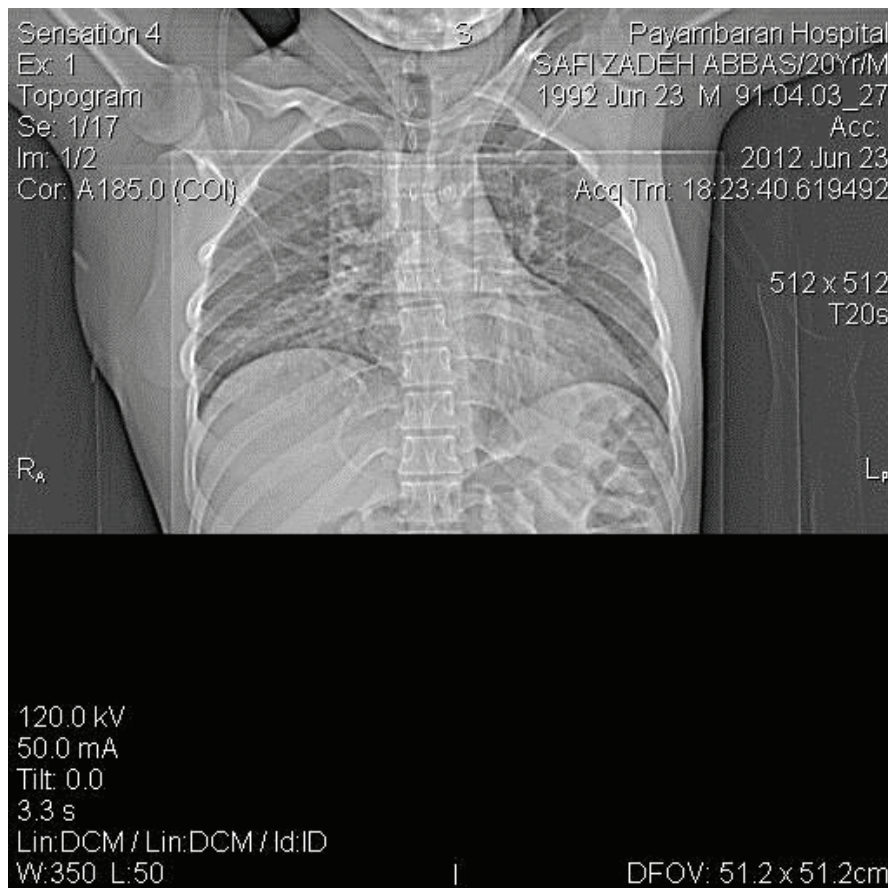


Figure 1. Patient's Normal Chest X-Ray

Surgical consultation made, found negative for any possible problems. We requested an abdominal ultrasonography, which reported no abnormalities observed in the subdiaphragmic, pelvic, hepatobiliary, pancreas, spleen and kidneys.

Since the patient was an immigrant from the TB prevalent region, we consulted with an infectious diseases specialist to exclude the possibility of such malady. In this respect, obtained sputum smears (three times) and the sputum culture for the B.K (later in two months) were negative.

We requested other Para clinical examinations such as lung's high resolution computerized tomography (HRCT), Spiral CT, pulmonary arteries CT angiography and the legs Doppler ultrasonography. Lung HRCT Scan (Fig.2) reported as "consolidations with air bronchogram were evident in both lungs' lower lobes, more prominent on the right side, which was suggestive of pneumonia or infection.

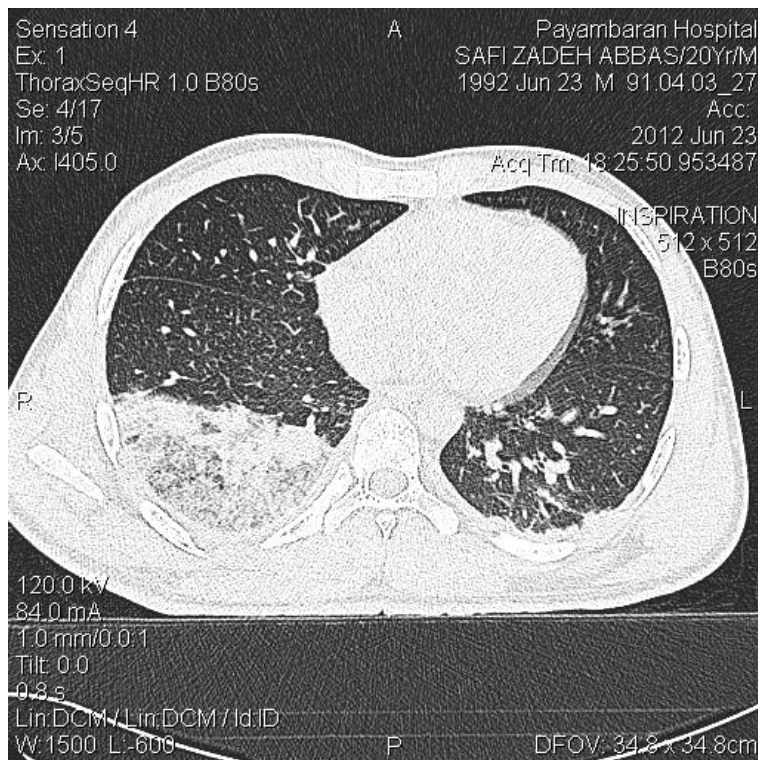


Figure 2. HRCT-Illustrating consolidations with air bronchogram

Spiral CT Scan (Fig.3) showed no other pulmonary paranchymal lesions and the pulmonary arteries CT angiography (Fig.4), as the most validated test for PTE diagnosis in our region, reported as "after injection of contrast medium with power injection with the rate of 4 ml/s, pulmonary arteries were opacified. The main trunk of pulmonary artery and the left main pulmonary arteries had normal course with no evidence of any stenosis or pathologic dilatation or thrombosis. Filling defects are evident in distal of right pulmonary artery that is extended to all lobar branches of right lung. Small filling defects are also noted in distal branches of pulmonary arteries of the left lower lobe. Above descriptions were consistent with the diagnosis of pulmonary

thromboembolism". Doppler ultrasonography of the legs was normal.

Based on this young patient's above mentioned clinical and Para clinical facts, we diagnosed him as post appendectomy PTE and treated him accordingly with the Antibiotic (Ceftazidine), Heparin (Enoxaprin) and in follow with Warfarin (Coumadin) i conventionally. We discharged him with an acceptable clinical condition after ten days and advised him to return for follow-ups in two weeks. We also guided him to take Warfarin for six months along with INR checks.

Clinical follow-ups in six months showed the patient's complete recovery.

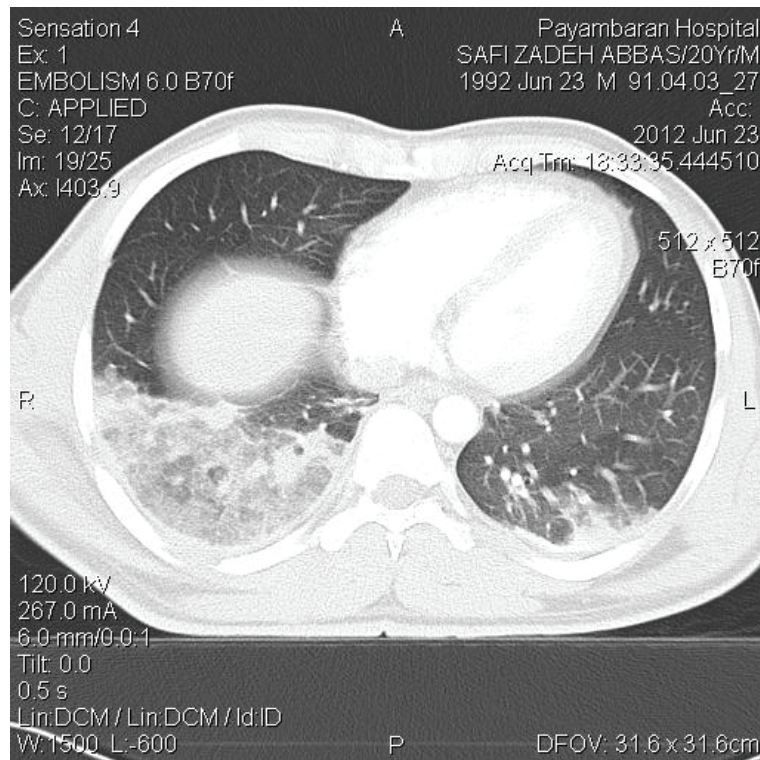


Figure 3. Spiral CT, showing no pulmonary parenchymal lesions

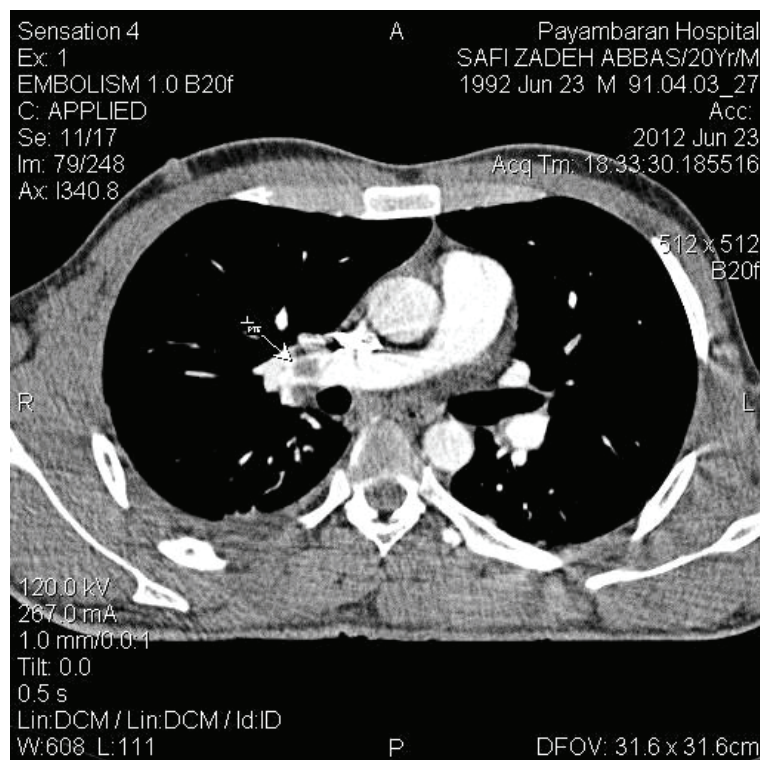


Figure 4. Pulmonary angiography showing opacified pulmonary artery with the right side filling defect

Discussion

All clinicians have been faced with many different atypical presentations of different maladies. A well-known classical disease may manifest itself in other modes of history, physical exam finding, and subjectivity and objectivity values. These aforementioned facts, obviously should be communicated seriously, otherwise missing some crucial clues, may result negative credits for the clinician's proper assessment and precise treatment. In this case, we have learned, PTE can be appeared in an individual who has no significant underlying factor for such chaos. Our patient was young and did not have any history hematological hypercoagulable state. He also was not undergone a very major and complicated surgery. He was not remarkably immobile and bedridden in the Hospital for a long period of time. There were also no history of DVT, malignancy or notable diseases in his present and his past medical reviews. Thus by presenting this PTE case, we hoped to allocate our atypical experience in this atypical but still the possible complication of a young male's post appendectomy.

Conclusion

In brief, this case presentation provides a constellation of alarming sings which engage the clinician's mind for the necessity of becoming watchful while facing a suspected case of PTE. Any sudden onset of shortness of breath in a patient, who has undergone any type of surgery or has been immobilized long in the hospital bed, may be one the most staggering sign in PTE. Such shortness of breath could be along with the patient's anxiety and

an unreasonable apprehension and tachycardia. The patient may restlessly complain of a chest pain which is more rigorous during inspiration. As this case showed, PTE clients may show a productive cough which is foamy mucous at first and later gets bloody. As we found in this patient, chest physical exam was not too revealing. Sometimes, in PTE a pleural friction rub may be audible over the lung tissue, where its blood supply has been impeded by thrombus. We did not find abnormality in the patient's Chest X-Ray, but occasionally in some PTE, pleural effection may be shown. As the most common source of thrombus formation and embolization are the patient's leg proximal deep venous and or the pelvis veins thrombosis, these areas may be checked for evidence of any abnormality and positive physical findings. Lastly, the ultimate PTE diagnosis is relied upon, not only on validated clinical criteria, but also combined with other paraclinical tests. In most cases if PTE gets assessed, diagnosed and treated early, more likely, the patient survives, otherwise even with the more complicated mode of therapy (thrombolysis, Inferior vena cava filtering and surgical thrombectomy), in most cases the patient's death is not infrequent.

Acknowledgment:

The authors wish to express thanks to the Payambaran Hospital patient records office and the radiology department for their helps. Special gratitude goes to Ms. Zahra Eftekhari for her secretarial assists.

References

1. Udgiri N, Curras E, Kella VK, Nagpal K, Cosgrove J. Appendicitis, is it an emergency? *American surgeon*. 2011 Jul;77(7):898-901. PubMed PMID: 21944355.
2. Takeda M, Higashi Y, Shoji T, Hiraide T, Maruo H. Necrotizing fasciitis caused by a primary appendicocutaneous fistula. *Surgery today*. 2012 Aug;42(8):781-4. PubMed PMID: 22318638. Pubmed Central PMCID: 3396344.
3. Wilms IM, de Hoog DE, de Visser DC, Janzing HM. Appendectomy versus antibiotic treatment for acute appendicitis. *Cochrane database of systematic reviews*. 2011 (11):CD008359. PubMed PMID: 22071846.
4. Strasberg SM, Hall BL. Postoperative morbidity index: a quantitative measure of severity of postoperative complications. *Journal of the American College of Surgeons*. 2011 Nov;213(5):616-26. PubMed PMID: 21871822.
5. Ravari H, Jangjoo A, Motamedifar J, Moazzami K. Oral metronidazole as antibiotic prophylaxis for patients with nonperforated appendicitis. *Clinical and experimental gastroenterology*. 2011;4:273-6. PubMed PMID: 22235170. Pubmed Central PMCID: 3254204.
6. Paajanen H, Gronroos JM, Rautio T, Nordstrom P, Aarnio M, Rantanen T, et al. A prospective randomized controlled multicenter trial comparing antibiotic therapy with appendectomy in the treatment of uncomplicated acute appendicitis (APPAC trial). *BMC surgery*. 2013 Feb 8;13(1):3. PubMed PMID: 23394263.
7. Silva Vieira M, Anjo D, Antunes N, Carvalho H, Torres S. Pulmonary embolism with thromboembolus in transit. *Revista portuguesa de cardiologia : orgao oficial da Sociedade Portuguesa de Cardiologia = Portuguese journal of cardiology : an official journal of the Portuguese Society of Cardiology*. 2013 Jan;32(1):71-2. PubMed PMID: 23246267.
8. Konstantinides S, Lankeit M. Pulmonary embolism hotline 2012. Recent and expected trials. *Hamostaseologie*. 2013 Feb 8;33(1):43-50. PubMed PMID: 23337923.
9. Wilbur J, Shian B. Diagnosis of deep venous thrombosis and pulmonary embolism. *American family physician*. 2012 Nov 15;86(10):913-9. PubMed PMID: 23157144.
10. Patel AP, Koltz MT, Sansur CA, Gulati M, Hamilton DK. An analysis of deep vein thrombosis in 1277 consecutive neurosurgical patients undergoing routine weekly ultrasonography. *Journal of neurosurgery*. 2012 Dec 14. PubMed PMID: 23240698.

11. Louzir B, Mehiri N, Cherif J, Zakhama H, Toujani S, Ben Salah N, et al. [Diagnosis approach of pulmonary embolism]. *La Tunisie medicale*. 2012 Nov;90(11):759-63. PubMed PMID: 23330217. Strategie diagnostique au cours de l'embolie pulmonaire.
12. Lee WS, Kim KI, Lee HJ, Kyung HS, Seo SS. The Incidence of Pulmonary Embolism and Deep Vein Thrombosis After Knee Arthroplasty in Asians Remains Low: A Meta-analysis. *Clinical orthopaedics and related research*. 2012 Dec 22. PubMed PMID: 23264001.
13. Huisman M, Klok F. Diagnostic management of acute deep vein thrombosis and pulmonary embolism. *Journal of thrombosis and haemostasis : JTH*. 2013 Jan 7. PubMed PMID: 23294863.
14. Granziera S, Rechichi A, De Rui M, De Carlo P, Bertozzo G, Marigo L, et al. A new D-dimer cutoff in bedridden hospitalized elderly patients. *Blood coagulation & fibrinolysis : an international journal in haemostasis and thrombosis*. 2013 Mar;24(2):109-12. PubMed PMID: 23249613.
15. Zwaan L, Thijs A, Wagner C, Timmermans DR. Application of an evidence-based decision rule to patients with suspected pulmonary embolism. *Journal of evaluation in clinical practice*. 2012 Dec 28. PubMed PMID: 23279113.
16. Zhu L, Wang JG, Liu M, Guo XJ, Guo YL, Zhai XH, et al. [Anatomic distribution of embolus at CT pulmonary angiography in patients suspected acute pulmonary embolism]. *Zhonghua jie he he hu xi za zhi =Zhonghua jiede he huxi zazhi = Chinese journal of tuberculosis and respiratory diseases*. 2012 Nov;35(11):833-6. PubMed PMID: 23290039.
17. Weberova D, Weber P, Kubsova H, Meluzinova H, Polcarova V, Ambrosova P, et al. Occurrence of pulmonary embolism among 260 in-patients of acute geriatric department aged 65+ years in 2005-2010. *Advances in gerontology =Uspekhi gerontologii / Rossiiskaia akademiia nauk, Gerontologicheskoe obshchestvo*. 2012;25(3):506-12. PubMed PMID: 23289231.
18. Yhim HY, Jang MJ, Kwak JY, Yim CY, Choi WI, Lee YC, et al. The incidence, risk factors, and prognosis of recurrent venous thromboembolism (VTE) in patients with advanced solid cancers receiving anticoagulation therapy after the diagnosis of index VTE. *Thrombosis research*. 2013 Feb 9. PubMed PMID: 23399441.
19. Tsung AH, Williams JB, Whitford AC. Sixteen-Year-old Athlete with Chest Pain and Shortness of Breath due to Pulmonary Emboli. *The Journal of emergency medicine*. 2013 Jan 23. PubMed PMID: 23351571.
20. Parast L, Cai B, Bedayat A, Kumamaru KK, George E, Dill KE, et al. Statistical methods for predicting mortality in patients diagnosed with acute pulmonary embolism. *Academic radiology*. 2012 Dec;19(12):1465-73. PubMed PMID: 23122566.