

## Non Surgical Treatment of Established Forearm's Volkmann Contracture in Child: A Case Report

Mryam Farzad; PhD Student; Seyed Ali Hosseini<sup>1</sup>; PhD.  
Nazila AkbarFahimi ; PhD Student, Fereydoun Layeghi ;MD,  
*University of Social Welfare and Rehabilitation Science, Tehran, Iran*

The acute compartment syndrome of the forearm is rare and may therefore be easily missed. Although many clinicians will not see such a patient during their entire career, profound knowledge of the symptoms is required to recognize the syndrome in time. Besides immediate identification of the compartment syndrome early surgical treatment is mandatory to avoid its devastating consequences. Then the functional results can be good, but it can't be correct in child because of more chance to survive necrotic muscle and regain motion with splinting and hand therapy.

This study reported the nonsurgical treatment for ischemic contracture of hand and forearm due to displaced supra-condylar fracture of the humerus at 6 years old boy, after fixed contractures.

**Key words:** Acute compartment syndrome / Volkmann's ischemic contracture / Child / Nonsurgical Treatment / Splinting / Hand Therapy

Submitted: 16 January 2010

Accepted: 03 March 2010

### Introduction

Acute compartment syndrome and the subsequent development of Volkmann's ischemic contracture can be one of the most devastating complications of pediatric trauma. Prompt recognition and treatment of an acute compartment syndrome reduces the overall morbidity associated with this condition. However, prolonged ischemia can result in irreversible changes in the muscles, nerves, and vascular endothelium, leading to permanent disability of the hand and wrist. This end result of ischemia is what is known as Volkmann's ischemic contracture as shown in figure 1.

### History

Richard von Volkmann in 1881, was one of the first to describe ischemic muscle paralysis and contracture. Before this, a few case reports of hand and wrist deformity following injury had been described (1,2); however, paralysis and contracture were attributed to neurologic injury (2).

Volkmann was probably the first to thoroughly describe this entity and attribute the cause to muscle ischemia. He described a progressive posttraumatic muscle contracture that did not respond to splinting, and attributed the contracture to ischemia and

subsequent muscle necrosis. Hildebrand, in 1890, was the first to use the term Volkmann's contracture (2).

Subsequent animal investigations and a thorough clinical description by Leser in 1884 brought further attention to this condition, its presentation, and etiology. He considered the pathologic findings in the muscle to be a result of oxygen deprivation to the muscle, but did not discuss the etiology of the oxygen deprivation. Several early investigators pursued the concept of a vascular disturbance, such as venous stasis, leading to muscle

ischemia. The concept of increasing internal pressure within the forearm evolved (2-5). By 1928, the core opinion

on the etiology of contracture was that of increased pressure within the muscle compartment. The contracture was caused by pressure applied from without (ie, the tight bandaging described by Volkmann), from within, or from a combination of both (6). The notion that arterial injury alone was the cause of ischemia gradually replaced the concept of pressure ischemia, likely because of the problems associated with arterial injuries during World War I (7,8).

1- All corresponding to: Dr. Seyed Ali Hosseini. E-mail: s\_alihosseini@hotmail.com

As the pathogenesis of ischemic contracture was better understood, treatment of impending Volkmann's ischemic contracture (acute Compartment syndrome) became more refined(9,10).

Eichler and Lipscomb (11) outlined the early technique of fasciotomy. Significant advances in the methods of diagnosis and monitoring of compartment pressures were introduced by Whitesides, Hargens, Mubarak, and Matsen (12-15). Refinements in surgical technique were described further by Eaton and Green, Whitesides, Gelberman, and others (15-17). The recognition and treatment of acute compartment syndrome have greatly diminished the incidence and severity of Volkmann's ischemic contracture. Volkmann's ischemic contracture is the end result of prolonged ischemia of the muscles and nerves in an extremity. Most commonly, this is caused by untreated or prolonged ischemia from an acute compartment syndrome. High tissue fluid pressures within a muscle compartment reduce capillary perfusion below a level necessary for tissue survival. Sustained ischemia can result in irreversible changes to the muscle, which undergoes necrosis. The necrotic muscle is replaced with fibrotic tissue, clinically presenting as contracture. Experimental studies have produced irreversible muscle necrosis after 4 hours of ischemia (12-18). In the forearm, the pattern of necrosis involves an elliptically shaped area in the middle third of the forearm (19). The necrotic muscle is replaced by fibroblasts, which cause adhesions to the surrounding tissue and contract in both longitudinal and horizontal planes. The maturation of the fibrotic tissue occurs over 6 months to a year, allowing the severity of the clinical contracture to progress over this time. Permanent nerve injury can occur from the initial insult. More nerve impairment occurs as the necrotic muscle becomes more fibrotic and compresses the nerve. Nerve function is impaired further by the inability of the nerve to glide through a fibrotic tissue bed. Nerve circulation is also diminished by the dense fibrotic tissue. On surgical exploration, the nerve can be markedly constricted and atrophic, with the appearance of a thin line of tissue. Dissection of the nerve through this dense scar tissue and extensive neurolysis may result in further neurologic injury.

### **Clinical presentation**

The clinical presentation of acute compartment syndrome differs from that of the established Volkmann's contracture.

Diagnosis of acute Compartment syndrome remains principally a Clinical diagnosis. Certain types of injuries should Raise the index of suspicion for the

development of compartment syndrome. In children, the most frequent injury associated with compartment syndrome is the displaced supracondylar fracture of the humerus (14,20,21). With the increased use of closed reduction and pinning for supracondylar humerus fractures, the incidence of compartment syndrome associated with this injury has decreased (22). Diaphyseal forearm fractures are also a frequently associated injury, with 15% to 22% of ischemic contractures occurring as a Complication of forearm fracture (14,22-24).

Also, cast immobilization with the elbow at 90 degrees or more of flexion has been a common Associated finding. The hallmark of diagnosis is a swollen, tense, and tender compartment that does not improve with elevation. Several authors have described additional clinical findings associated with the diagnosis of compartment syndrome. Over time these have been refined to the "5 p's" of diagnosis:

– **Pain.** Pain is out of proportion to the injury, often causing a patient to have a progressively increasing narcotic requirement. Even with increasing pain medications, the pain is not relieved. **Pain with passive motion.** Passive stretching of the fingers or wrist causes pain in the ischemic compartment. **Pallor.** This has been seen in some cases. Usually this is associated with a proximal vascular compromise affecting the brachial artery. This may be tenting of the artery across the fracture site, arterial spasm due to adjacent trauma, or arterial thrombosis secondary to intimal injury. – **Pulse lessness.** This can be associated with pallor.

Pulselessness is a rare finding and usually occurs late in the diagnosis. – **Paresthesia** and paralysis. These Conditions are variably present. Jepson (2) stated that "within a few hours, the patient complains that the fingers are numb. The patient is usually more concerned than the surgeon." Although numbness and paresthesias have been described as the first clinical finding (26,27).

Sensory findings of dyesthesia, hypesthesia, or anesthesia caused by a compartment syndrome are distal to the affected compartment. Sensory findings usually precede motor findings. Established Volkmann's contracture has a much different presentation. It has a broad clinical spectrum, based on the extent of muscle necrosis and nerve injury that has occurred. The deformity results from the ischemic event and subsequent muscle fibrosis and nerve dysfunction, either from the initial insult or secondary to the subsequent scarring and vascular compromise to The most vulnerable muscle group is the deep flexor compartment of the forearm, which includes the flexor digitorum profundus (FDP) muscle and the flexor pollicis longus (FPL) (28-34)..

In the mildest form of ischemic contracture, it is these muscles that are affected, and often only a portion of these muscles. Typically, the ring and long fingers are the most commonly affected profundus muscles. Next most common is the FPL, followed by the index and small fingers (35-37). The flexor digitorum superficialis, pronator- teres, and wrist flexors are involved with more severe or prolonged ischemia. In the most severe cases, ischemia and subsequent necrosis of the extensor compartment can occur as well. As the area of necrosis expands, there is greater involvement of the nerves. The median nerve is more susceptible to ischemia and subsequent fibrosis than the ulnar nerve. In severe cases, the posture of the wrist is in flexion, sometimes with associated forearm pronation. The position of the fingers is variable, ranging from a simple claw deformity with flexion of the metacarpophalangeal and interphalangeal joints to an intrinsic plus or intrinsic minus posture, depending on the involvement of the ulnar nerve or the involvement of the hand intrinsic muscles. The intrinsic minus deformity is seen more commonly than the intrinsic plus deformity because of the greater strength of the extrinsic flexor and extensor muscles. Flexion of the wrist usually allows active and passive extension of the fingers. However, chronic muscle imbalance and failure to maintain passive range of motion lead to stiff and contracted joints (35-38).

It is important to distinguish a true Volkmann's contracture from a pseudo-Volkmann's contracture. Pseudo-Volkmann's is caused most commonly by entrapment or tethering of the FDP or the FPL to the fractures of the radius or ulna.

Other causes include adhesions around internal fixation, tendon rupture, crush injury, and scarring secondary to infection (39). Clinically, this can be very difficult to distinguish from a true Volkmann's contracture, especially from a mild Volkmann's ischemia (39-40). At surgical exploration, the muscles will appear normal, but adherent to the bone. A myotomolysis or tenolysis alone will usually allow correction. Because muscle entrapment at the fracture site is one of the more frequent causes of pseudo-Volkmann's, it is important to check passive range of motion of the digits following reduction. Extension is affected most commonly due to entrapment of the deep flexors. This can be corrected easily with open reduction of the fracture.

### **Classification**

Several classification systems have been described, with considerable overlap. Most are based on the

clinical severity of the presentation and are used to help direct the appropriate treatment for the identified disability. Most investigators recognize the tremendous variability of the clinical presentations (36-38,41,42).

#### ***Diffuse but moderate ischemia.***

The main feature in this presentation is contracture. Nerve involvement is limited and resolves spontaneously. Most function returns spontaneously, and at the end of a few months there is left only residual contracture to correct.

#### ***Intense but localized muscle damage.***

This occurs rarely, but with a distinct presentation in which the primary involvement is that of the deep flexors of the forearm, specifically FDP and FPL. Minimal involvement of the median nerve adjacent to the zone of infarction can also be present.

#### ***Widespread necrosis or fibrosis.***

In this presentation there is near total destruction of all the muscles of the forearm. The median and ulnar nerve function is compromised, and there may be extension of the infarct into the dorsal compartment. As noted by Zancolli (38) there is significant variability in the involvement of the hand. His classification system was based entirely on the involvement of the intrinsic muscles. Type I cases have no intrinsic involvement (simple claw deformity). In Type II deformity, the intrinsic muscles are paralyzed, resulting in an intrinsic minus claw hand and opponens paralysis. Type III deformity is defined by intrinsic muscle contracture with the clinical appearance of an intrinsic plus hand and intrinsic plus thumb. In the Type IV combined group, there is a mixed presentation of intrinsic involvement. At times there may be some fingers with an intrinsic minus posture (usually the 4th and 5th fingers), with an intrinsic plus posture affecting the adjacent fingers (usually the index and middle). The variability in presentation depends on the ischemic insult and potential recovery to the median and ulnar nerves, and there

is no uniform pattern to predict whether the thenar or hypothenar muscles will be spared or the extent of the intrinsic paresis or paralysis. Perhaps the most commonly used classification system is that of Tsuge (36). He classified established Volkmann's contracture into mild, moderate, and severe types, according to the extent of the muscle involvement.

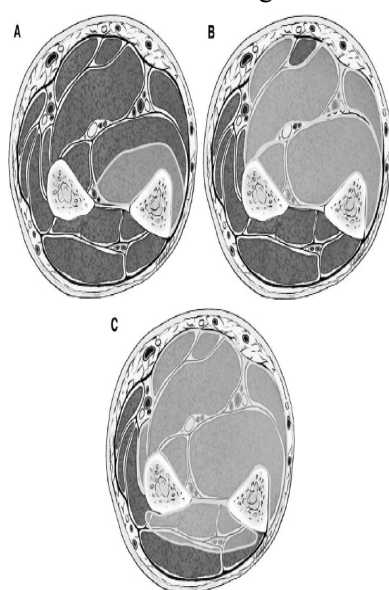
The mild type, also described as the localized type, involves the muscles of the deep flexor compartment of the forearm, usually involving only the FDP of

the ring or middle fingers as shown in figure 2A. It can involve all the FDP and the FPL as well. Nerve involvement is absent or mild, typically consisting of sensory changes which resolve spontaneously. With wrist flexion, the fingers can be fully extended. Most of the mild type result from direct trauma, either from crush injury or forearm fractures, and are typically seen in young adults.

In the moderate type, the muscle degeneration includes all or nearly all of the FDP and FPL, with partial degeneration of the flexor superficialis muscles as shown in figure 2B. Neurologic impairment is always present. Sensory impairment is generally more severe in the median than in the ulnar nerve, and the hand demonstrates an intrinsic minus posture. Moderate-type injury is most commonly the result of supracondylar humerus fractures in children between ages 5 and 10.

The severe type involves degeneration of all the flexor muscles of the fingers and the wrist. There is central muscle necrosis, and varying involvement of the extensor compartment as shown in figure 2C. Neurological deficits are severe, including complete palsy of all the intrinsic muscles of the hand. Tsuge categorized those cases that may have had moderate involvement initially but, because of fixed joint

*Fig 2(A,B,C) The mild , moderate and sever type of established Volkmann's contracture according to the extent of the muscle involvement. The mild type, or localized type, involves the muscles of the deep flexor compartment. In the moderate type, the muscle degeneration includes all or nearly all of the FDP and FPL. The severe type involves degeneration of all the flexor muscles of the fingers and the wrist.*



contractures, scarred soft tissue envelope, or failed surgeries, were categorized as severe. As with moderate cases, severe cases are most commonly the result of supracondylar humerus fractures in children. Within each classification type, there is a broad range of clinical presentation. This heterogeneity of presentation makes it difficult to apply a specific treatment based solely on classification systems, and makes it nearly impossible to provide meaningful outcome and comparison studies.

### Treatment

Acute compartment syndrome should be treated with emergent fasciotomy as soon as the condition is identified.

### Nonsurgical management

Nonsurgical management should be instituted early in most cases of established Volkmann's contracture.

### History of Patient

A 6 years old boy attended hand therapy in Iran rehabilitation hand center with a compliant of volkmann ischemia due to displaced supracondylar fracture of the humerus 2 month ago.

At first observation he had elbow and wrist flexion forearm pronation and clawing hand. no active flexion in wrist and fingers and pain to passive flexion (5 due to VAS criteria). volkman angle were 75 degree. MP joints were in 25 degree hyperextension, PIP Joints in 75 degree flexion and DIP joints in 25 degree flexion and all them were fixed in that degree without any active or passive flexion.

In sensory evaluation he had loss of protective sensation in median nerve distribution and residual deep pressure in ulnar nerve distribution as shown in figure 3.

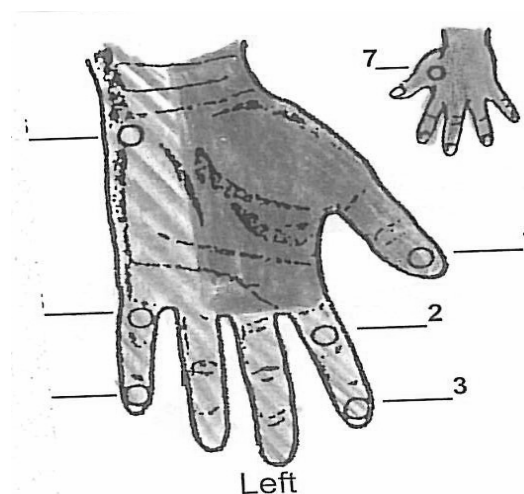


fig 3, first sensory evaluation in median nerve distribution we have loose of protective sensation and other area we have residual deep pressure

IN elbow he had 60 degree extension lag and 120 degree active and 130 degree passive flexion as shown in figures4,5

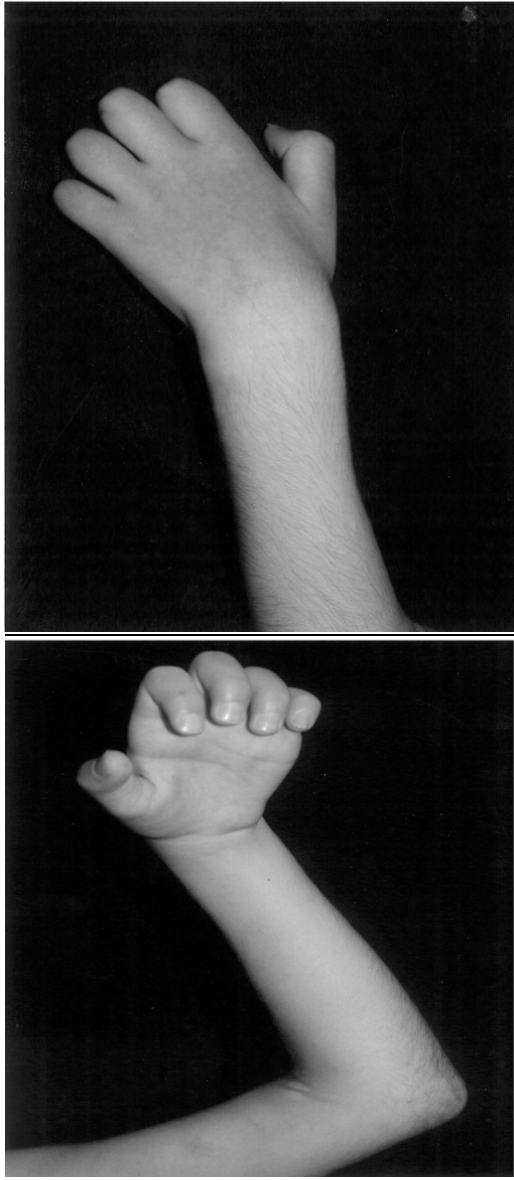


Fig 4-5 , hand appearance in first visit look at clawing position

According to evaluation he was in type 2 Zancolli and moderate type of TSUge.

**Treatment plan**

Maintain of passive joint motion and preservation and strengthening of remaining muscle function, and correction of deformity through a program of

splinting , sensory reeducation (it is expected to be regenerate in moderate cases)muscle reeducation were our treatment goals. To obtain the goals therapy was begun with heat , active ROM of involved jointe , stretching of involved joints till pain eliction,hand inverse and contact with many type of sensory feedbacks to reeducation .

Static progressive splint for extending elbow wrist and plus position of fingers in tolerable degree and dynamic MP flexor for day time.after achieving some degree of active flexion, isometric exercise were included. Therapy was done 6 day a week under therapist supervision and followed in home as directed with play hand in water freely.

**Re-evaluation**

He was evaluated monthly and the last one was one year after diagnosis .

NO elbow extension lag were detected , volkmann degree was 0 in last observe.no clawing deformity in fingers . But he had extension deficiency in wrist and figers Spontaneously movement, that may be due to writing position , because he is left hand dominancy.

In sensory evaluation there was diminished light touch sensation in ulnar nerve distributions.(fig 6)

**Discussion**

In children, there may be more recovery of nerve and muscle function over time. immediate surgical intervention in children, with the exception noted above for severe cases when early liquefactive necrosis is present. A formal program of splinting and therapy can improve the outcome of later surgical intervention and may result in less extensive surgical corrections. Therapy should be directed toward maintenance of passive joint motion, preservation and strengthening of remaining muscle function, and correction of deformity through a program of splinting. Alternating dynamic and static splinting has been advocated. However, the authors prefer the use of static progressive splinting for fixed contractures of the wrist, fingers, and thumb web space.

Mild contractures with minimal to no nerve involvement can often be treated only with a comprehensive program of hand therapy and rehabilitation. Even for moderate to severe involvement, long-term customized splinting may be necessary to augment hand function.

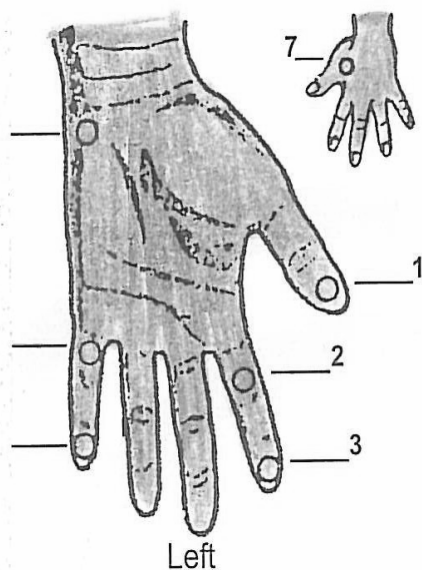


Fig 6. sensory re-evaluation test , we have normal sensation in median nerve distribution and residual texture sensation in other area

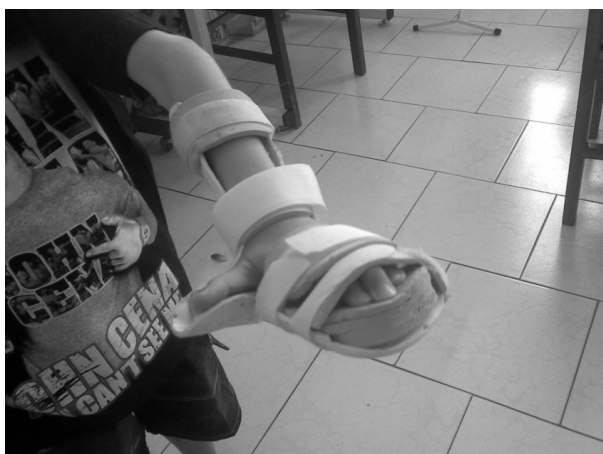

Fig 7,final splint (night time) he use knuckle bender in day time

### Aknowledgements

We gratefully acknowledge the very helpful participation of the patient ,his family and Staff from hand ward at ASMA Center without whose contribution, this study wouldnot have been completed.

### References

1. Volkmann R. Die ischaemischen muskellaehmungen und kontrakturen. Centrabl f Chir 1881;51: 801.
2. Jepson P. Ischaemic contracture.Experimental study. Ann Surg 1926;84(6):785-93.
3. Murphy J. Myositis. JAMA 1914;63:1249-55.

4. Bardenheuer L. Die entstehung und behandlung der ischaemischen muskelcontractur und gangran. Dtsch Z Chir 1911;108:44.
5. Trice M, Colwell C. A historical review of compartment syndrome and Volkmann's ischemic contracture. Hand Clin 1998;14(3):335-41.
6. Jones R. Volkmann's ischaemic contracture with special reference to treatment. BMJ 1928;2:639-42.
7. Leriche R. Surgery of the sympathetic system. Indications and results. Ann Surg 1928;88:449.
8. Griffiths D. Volkmann's ischaemic contracture. Br J Surg 1940;28:239-60.
9. Holden C. Compartmental syndromes following trauma. Clin Orthop Relat Res 1975;113:95-102.
10. Holden C. The pathology and prevention of Volkmann's ischaemic contracture. J Bone Joint Surg Br 1979;61B(3):296-300.
11. Eichler G, Lipscomb P. The changing treatment of Volkmann's ischemic contractures from 1955-1965 at the Mayo Clinic. Clin Orthop Relat Res 1967; 50:215-23.
12. Hargens A, Schmidt DA, Evans KL, et al. Quantitation of skeletal muscle necrosis in a model compartment syndrome. J Bone Joint Surg Am 1981;63A(4): 631-6.
13. MatsenFA III, Mayo KA, Sheridan GW, et al. Continuous monitoring of intramuscular pressure and its application to clinical compartment syndromes. Bibl Anat 1977;15(1):112-5.
14. Mubarak S, Carroll N. Volkmann's contracture in children: aetiology and prevention. J Bone Joint Surg Br 1979;61B(3):285-93.
15. Whitesides T, Haney T, Morimoto K, et al. Tissue pressure measurement as determinant for the need of fasciotomy. Clin Orthop Relat Res 1975; 113:43
16. Eaton R, Green W. Epimysiotomy and fasciotomy in the treatment of Volkmann's ischemic contracture. Orthop Clin North Am 1972;3(1):175-86.
17. Gelberman R, Zakaib GS, Mubarak SJ, et al. Decompression of forearm compartment syndromes. Clin Orthop Relat Res 1978;134:225-9.
18. Brooks B. Pathologic changes in muscle as a result of disturbances of circulation. Arch Surg 1922;5: 188-216.
19. Seddon H. Volkmann's contracture: treatment by excision of the infarct. J Bone Joint Surg Br 1956; 38B(1):152-74.
20. Eaton R, Green W. Volkmann's ischemia: a volar compartment syndrome of the forearm. Clin Orthop Relat Res 1975;113:58-64.
21. Ultee J, Hovius S. Functional results after treatment of Volkmann's ischemic contracture: a long term followup study. Clin Orthop Relat Res 2005; 431:42-9.
22. Kadiyala R, Waters P. Upper extremity pediatric compartment syndromes. Hand Clin 1998;14(3): 467-75.
23. Matsen FA III, Veith R. Compartmental syndromes in children. J Pediatr Orthop 1981;1:33.
24. Sundararaj G, Mani K. Pattern of contracture and recovery following ischaemia of the upper limb. J Hand Surg (Br) 1985;10B(2):155-61.
25. Blakemore L, CoopermanDR, Thompson GH, et al. Compartment syndrome in ipsilateral humerus and forearm fractures in children. Clin Orthop Relat Res 2000;376:32-8.
26. Rolands R, Lond M. A case of Volkmann's contracture treated by shortening of the radius and ulna. Lancet 1905;2:1168-71.
27. Gulgonen A. Surgery for Volkmann's ischaemic contracture. J Bone Joint Surg Br 2001;26B(4): 283-96.

28. Bedbrook G. Neo-natal Volkmann's syndrome. *Proc R Soc Med* 1953;46(5):349.
29. Caouette-LaBerge L, Bortoluzzi P, Egerszegi EP, et al. Neonatal Volkmann's ischemic contracture of the forearm: a report of five cases. *Plast Reconstr Surg* 1992;90(4):621–8.
30. Engel J, Heim M, Tsur H. Late complications of neonatal Volkmann's ischaemia. *Hand* 1982;14(2): 162–3.
31. Kline S, Moore J. Neonatal compartment syndrome. *J Hand Surg (Am)* 1992;17A(2):256–9.
32. Silfen R, Amir A, Sirota L, et al. Congenital Volkmann-Leser ischemic contracture of the upper limb. *Ann Plast Surg* 2000;45(3):313–7.
33. Tsur H, Yaffe B, Engel Y. Impending Volkmann's contracture in a newborn. *Ann Plast Surg* 1980; 5(4):317–20.
34. Ragland R III, Moukoko D, Ezaki M, et al. Forearm compartment syndrome in the newborn: report of 24 cases. *J Hand Surg (Am)* 2005;30(5):997–1003.
35. Botte M, Keenan M, Gelberman R. Volkmann's ischemic contracture of the upper extremity. *Hand Clin* 1998;14(3):483–97.
36. Tsuge K. Treatment of established Volkmann's contracture. *J Bone Joint Surg Am* 1975;57A(7): 925–9.
37. Tsuge K. Management of established Volkmann's contracture. In: Green D, editor. *Green's operative hand surgery*. Philadelphia: Churchill Livingstone; 1999. p. 592–603.
38. Zancolli E. Classification of established Volkmann's ischemic contracture and the program for its treatment. In: Zancolli E, editor. *Structural and Dynamic Bases of Hand Surgery*. Philadelphia: JB Lippincott; 1979.
39. Littlefield W, Hastings III, Strickland J. Adhesions between muscle and bone after forearm fracture mimicking mild Volkmann's ischemic contracture. *J Hand Surg (Am)* 1992;17A(4):691–3.
40. Deeney V, Kaye JJ, Geary SP, et al. Pseudo-Volkmann's contracture due to tethering of flexor digitorum profundus to fractures of the ulna in children. *J Pediatr Orthop* 1998;18:437–40.
41. Seddon H. Volkmann's ischaemia. *BMJ* 1964;1: 1587–92.
42. nkeddache Y, Gottesman H, Hamidani M. Proposal of a new classification for established Volkmann's contracture. *Ann Chir* 1985;4(2):134–42.